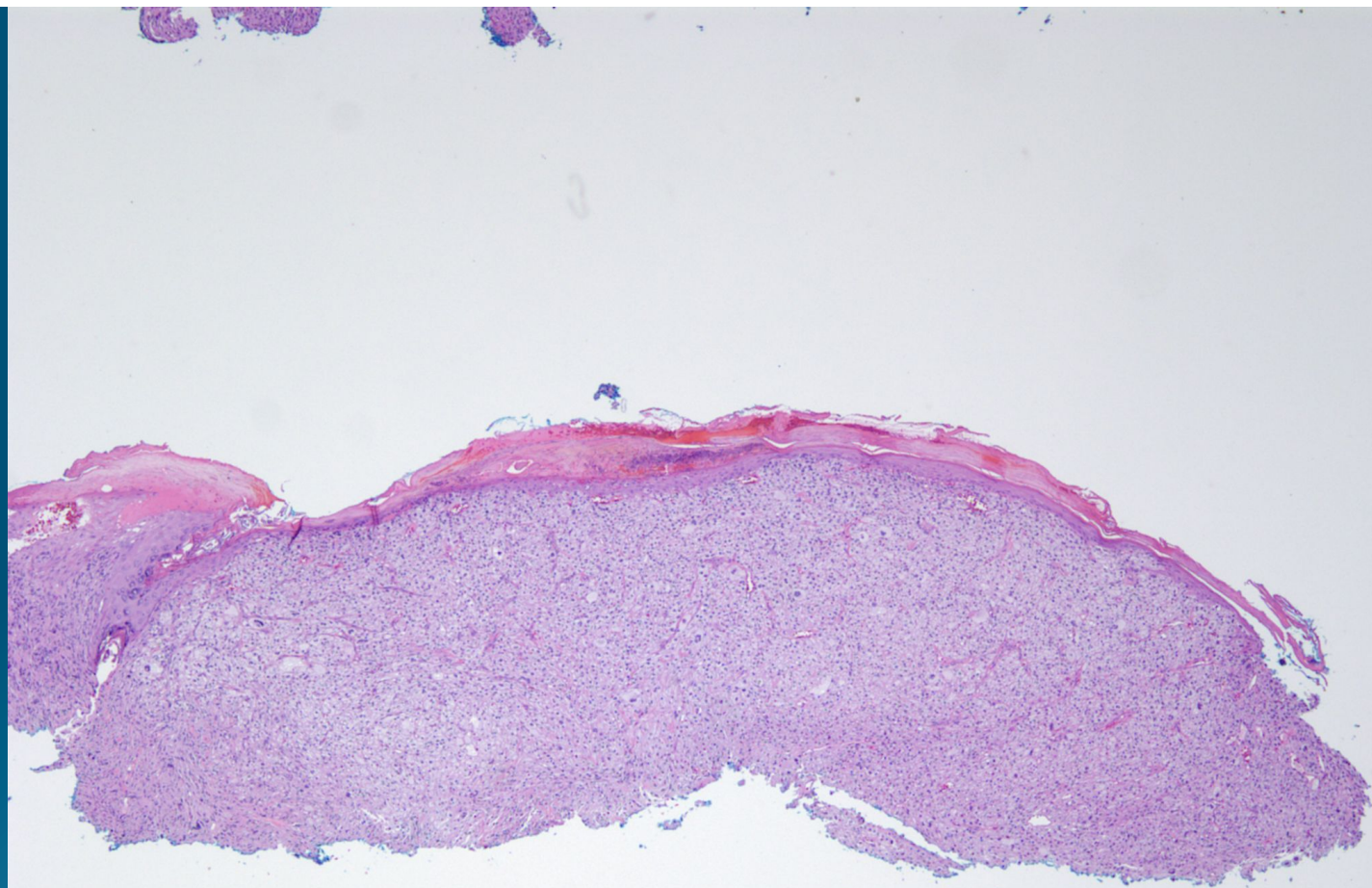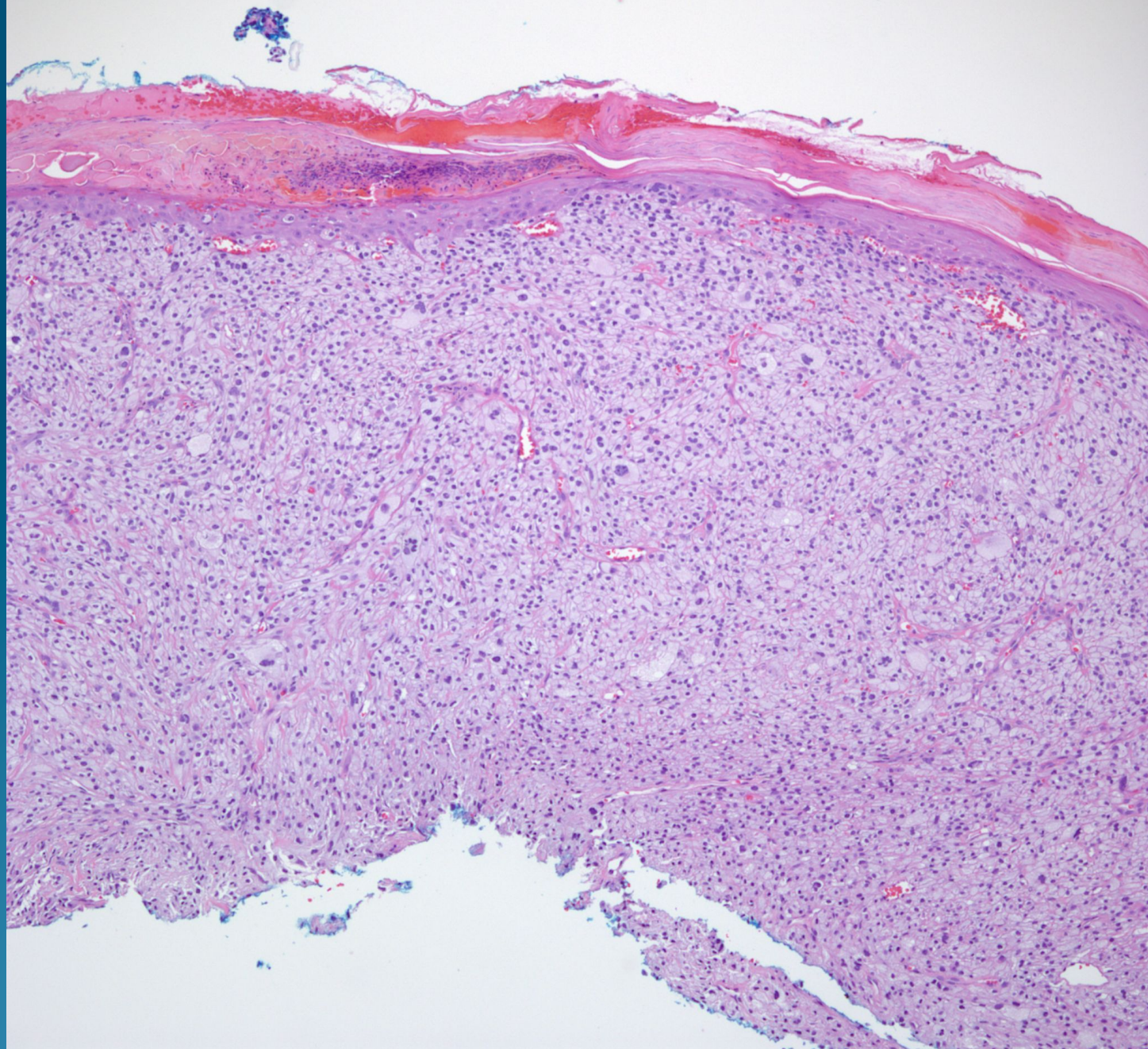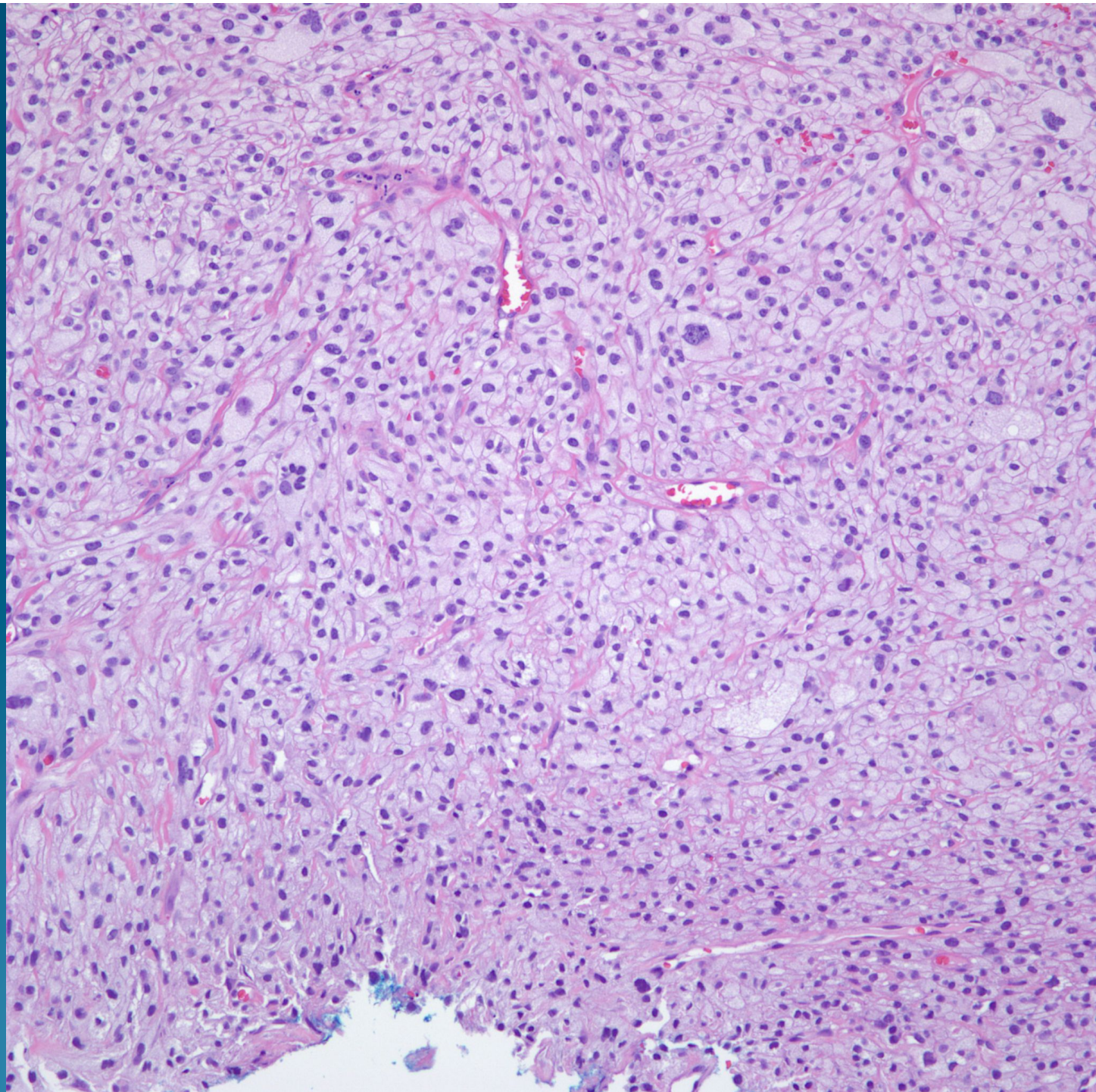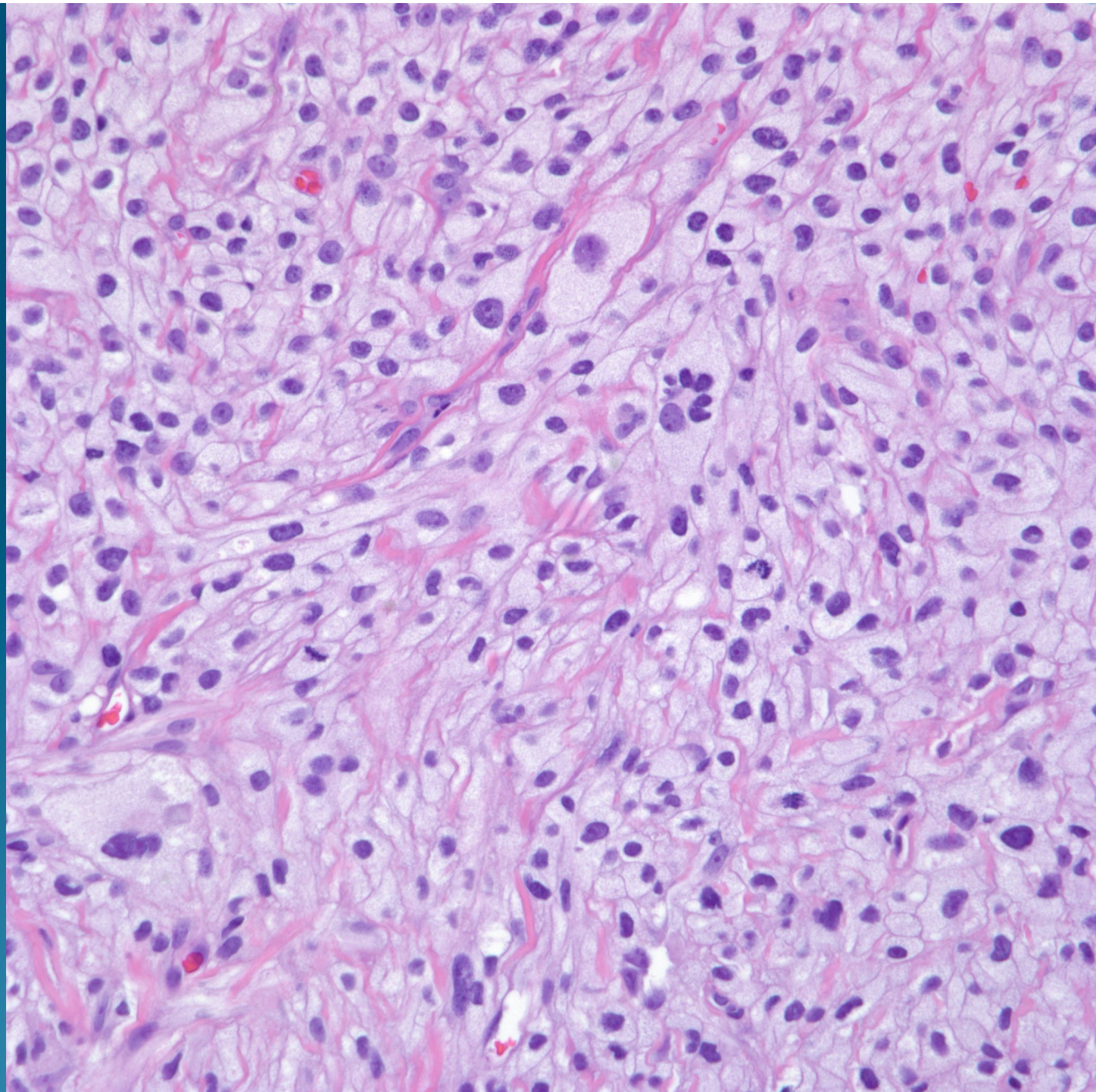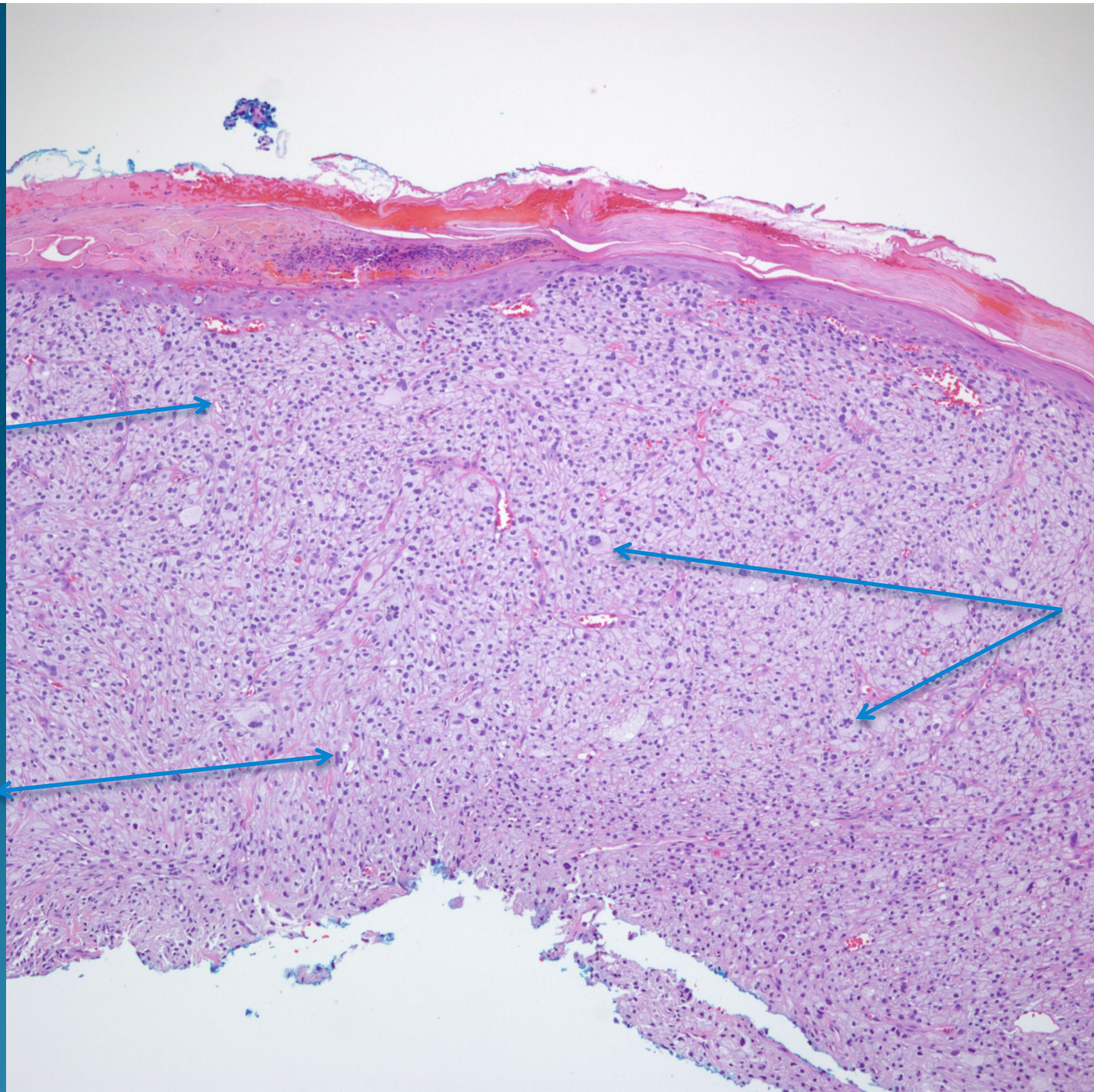


Atypical Fibroxanthoma with Clear Cell Features

Malignant
Cells with
Clear
cytoplasm

Atypical
Mitotic
Figures



Multi-
Nucleated
Tumor
Giant cells